

Discussion

Due to the low efficacy and high degree of compliance required for oral and topical treatments for onychomycosis, there is a demand for alternative treatment options that are both effective and lack serious side effects. Laser treatments have been previously shown to be able to pass through the nail plate and onto the nail bed, heating it up sufficiently to damage and inhibit growth of onychomycosis-causing pathogens.^{26,27} This study evaluated the effectiveness of the micropulsing PinPointe FootLaser as an alternative treatment option for onychomycosis.

Improved foot care management of keeping nails clean and trimmed and shoes disinfected, reduced use of restrictive footwear, and increased cleanliness in and around the shower are important to the clinical outcome of patients. Therefore, it is important to consider these factors when evaluating the results of this study because they may have contributed to the success rate. Furthermore, although we found successful lesion reduction of 68% with just one treatment, because greater success rates were also found when given more than one treatment, further studies are required.

In this study, subjects showed significant improvement in clear nail area and a significant reduction in lesion area after a follow-up averaging seven months. Additionally, side effects of the PinPointe treatment were minimal and included minor discomfort during the procedure, but nothing that was intolerable, as all subjects were able to complete the procedure.

Conclusion

Our data suggests that the 1064nm Nd:YAG PinPointe FootLaser should be considered as an effective alternative therapy to the typical oral and topical medications. Furthermore, the treatment is quick and easy to incorporate into a practice, yielding high patient satisfaction and increased revenues

www.cynosure.com

REFERENCES

- 1 Zakharlya Manevitch, Dmitry Lev, Malka Hochberg, Mila Palhan, Aaron Lewis, and Claes D Enk, "Direct Antifungal Effect of Femtosecond Laser on Trichophyton Rubrum Onychomycosis," *Photochemistry and Photobiology* 86: 476-479, 2010.
- 2 Kaur R, Kashyap B, and Bhalla P, "Onychomycosis: Epidemiology, Diagnosis and Management," *Indian Journal of Medical Microbiology*, 26: 108-116, 2008.
- 3 G. Botek, "Fungal Nail Infection: Assessing the New Treatment Options," *Cleveland Clinic Journal of Medicine*, 70: 110-114, 2003.
- 4 Robert Baran, "The Nail in the Elderly," *Clinics in Dermatology*, 29:54-60, 2011.
- 5 Singal A, and Khanna D, "Onychomycosis: Diagnosis and Management," *Indian Journal of Dermatological Venereology and Leprology*, 77:659-672, 2011.
- 6 Szepietowski JC, and Reich A, "Stigmatisation in Onychomycosis Subjects: A Population-Based Study," *Mycoses*, 52: 343-349, 2009.
- 7 Szepietowski JC, Reich A, Pacan P, Garlowska E, and Baran E, "Evaluation of Quality of Life in Subjects with Toenail Onychomycosis," by the Polish version of an international onychomycosis specific questionnaire, *Journal of the European Academy of Dermatology and Venerology*, 21: 491-48, 2007.
- 8 Roujeau JC, Sigurgeirsson B, Korting HC, Kerl H, and Paul C, "Chronic Dermatomycoses of the Foot As Risk Factors for Acute Bacterial Cellulites of the Leg: A Case-Control Study," *Dermatology*, 209: 301-307, 2004.
- 9 Iorizzo M, Piraccini BM, and Tosti A, "Today's Treatment Options for Onychomycosis," *Journal Der Deutschen Dermatologischen Gesellschaft*, 8: 875-879, 2010.
- 10 Chander Grover and Ananta Khurana, "An Update on Treatment of Onychomycosis," *Mycoses*, 2012.
- 11 Hall M, Monka C, Krupp P, and O'Sullivan D, "Safety of Oral Terbinafine: Results of a Post-Marketing Surveillance Study in 25,884 Subjects," *Archives of Dermatology*, 133: 1213-1219, 1997.
- 12 Stricker BH, van Riemsdijk MM, Sturkenboom MC, and Ottenvanger JP, "Taste Loss to Terbinafine: A Case-Control Study of Potential Risk Factors," *British Journal of Clinical Pharmacology*, 42: 313-318, 1996.
- 13 Carstens J, Wendelboe P, Sogaard H, and Thestrup-Pedersen K, "Toxic Epidermal Necrolysis and Erythema Multiforme Following Therapy with Terbinafine," *Acta Dermato-Venerologica*, 74: 391-2, 1994.
- 14 E Glyn V Evans, and Bárður Sigurgeirsson, "Double Blind, Randomised Study of Continuous Terbinafine Compared with Intermittent Itraconazole in Treatment of Toenail Onychomycosis," *BMJ*, 318: 1031-1034, 1999.
- 15 Gupta AK, and Gregurek-Novak T, "Efficacy of Itraconazole, Terbinafine, Fluconazole, Griseofulvin and Ketoconazole in the Treatment of Scopulariopsis Brevicaulis Causing Onychomycosis of the Toes," *Dermatology*, 202: 235-238, 2001.
- 16 Abadi D, and Zderic V, "Ultrasound-Mediated Nail Drug Delivery System," *Journal of Ultrasound in Medicine*, 30: 1723-1730, 2011.
- 17 David M. Harris, Brian A. McDowell, and John Strisower, "Laser Treatment for Toenail Fungus," *Proceedings of SPIE*, 7161, 2009.
- 18 Hochman LG, "Laser Treatment of Onychomycosis Using a Novel 0.65-Millisecond Pulsed Nd:YAG 1064-nm Laser," *Journal of Cosmetic and Laser Therapy*, 13: 2-5, 2011.
- 19 Hamish Dow, "Onychomycosis and Nail Dystrophy Treated with the PinPointe FootLaser," *Podiatry Now*, 2011.
- 20 Manevitch Z, Lev D, Hochberg M, Palhan M, Lewis A, and Enk CD, "Direct Antifungal Effect of Femtosecond Laser on Trichophyton Rubrum Onychomycosis," *Photochemistry and Photobiology*, 86: 476-479, 2010.
- 21 Kimura U, Takeuchi K, Kinoshita A, Takamori K, Hiruma M, and Suga, Y, "Treating Onychomycoses of the Toenail: Clinical Efficacy of the Sub-Millisecond 1064nm Nd:YAG Laser Using a 5mm Spot Diameter," *The Journal of Drugs in Dermatology*, 11(4):496-504, 2012.
- 22 ImageJ Software, <http://rsb.info.nih.gov/ij/docs/index.html>, accessed July 2012.
- 23 Siritantikorn S, Jintaworn S, Noisakran S, Suputtamongkol Y, Paris DH, and Blacksell, SD, "Application of ImageJ Program to the Enumeration of Orientia Tsutsugamushi Organisms Cultured In Vitro," *Transactions of the Royal Society of Tropical Medicine and Hygiene*, 2012.
- 24 Stojanovic VR, Jovanovic ID, Ugrenovic SZ, Vasovic LP, Zivkovic VS, Jovic MV, Kundalic BK and Pavlovic MN, "Morphometric Analysis of Nonsclerosed Glomeruli Size and Connective Tissue Content during the Aging Process," *Scientific World Journal*, 2012.
- 25 Fortin M, and Batte MC, "Quantitative Paraspinal Muscle Measurements: Inter-Software Reliability and Agreement Using OsiriX and ImageJ," *Physical Therapy*, 2012; 92(6): 853-864.
- 26 Hochman L, "Laser Treatment of Onychomycosis Using a Novel 0.65-millisecond Pulsed Nd:YAG 1064-nm Laser," *Journal of Cosmetic and Laser Therapy*, 2011; 13: 2-5.
- 27 Hashimoto T, and Blumenthal HJ, "Survival and Resistance of Trichophyton Mentagrophytes Arthrospores," *Applied and Environmental Microbiology*, 1978; 35(2): 274-277.

White Paper

Short Pulsed Nd:YAG Laser in the Treatment of Onychomycosis

Martine and Michael Abrahams

London Nail Laser Clinic

ABSTRACT

Purpose: To evaluate the efficacy of PinPointe™ FootLaser™ for the treatment of onychomycosis.

Design: A retrospective study of 12 subjects presenting with onychomycosis received treatment with the PinPointe short-pulsed Nd:YAG laser. Baseline and post follow-up photographs were taken to compare response rate. Planimetry using ImageJ software was used to calculate clear nail growth and lesion reduction.

Results: 100% of subjects responded to treatment. Subjects receiving one treatment achieved a 60% reduction in lesion area and 77% clear nail at follow up. Post one treatment, subjects showed 50% absolute clear nail growth. Subjects receiving up to three treatments achieved a 71% reduction in lesion area and 71% clear nail at follow up. Subjects who received multiple treatments showed 70% absolute clear nail growth, as compared to 50% for subjects who received one treatment.

Conclusions: PinPointe FootLaser is effective for the treatment of onychomycosis. Subjects receiving multiple treatments achieved better results than those receiving only one treatment.

INTRODUCTION

Onychomycosis is a common nail disorder affecting between 2-28% of the population¹ and its prevalence appears to be increasing.^{1,2} This infection is most prevalent in those who are immunosuppressed, individuals who experience frequent nail damage and the elderly –affecting up to 40% of this population.³

Dermatophytes, a homogeneous group of keratinophilic fungi, are the cause of over 90% of all cases of onychomycosis.⁴ The most common dermatophytes are *Trichophyton rubrum* and *Trichophyton mentagrophytes*. Additionally, *Candida* species and non-dermatophytic molds (NDMs) have also been implicated in the cause of onychomycosis.⁵

For those who are effected, onychomycosis can lead to additional medical, social and emotional issues. The primary concerns among subjects include the spread of infection to other nails or to other people, and others noticing the deformed nail(s). This can lead to a lowered self-esteem, poor body image, and depression. Physical problems associated with onychomycosis include difficulties with walking, pain, discomfort, trouble with clipping nails, and risk of acute bacterial cellulitis.^{7,8} Thus, onychomycosis is of considerable concern to the population.

Today, three main methods, topical, oral and device-related therapies, are currently employed to treat onychomycosis.^{9,10}

Oral treatments, such as Terbinafine, Itraconazole, Fluconazole, Griseofulvin, Ketoconazole, Posaconazole, and Ravuconazole, interfere with ergosterol synthesis in fungi, halting their growth. Terbinafine, for example, is an allylamine derivative, interfering with fungal cell membrane synthesis and causing fungal toxicity. However, treatment with Terbinafine does pose the risk of potential side effects including gastrointestinal disturbances,^{11,12} skin rashes,¹³ pancytopenia, agranulocytosis, drug interactions and drug resistance; and its efficacy remains limited. Other oral medications such as Itraconazole (a fungistatic triazole¹⁴), and Ketoconazole can produce significant adverse effects, including severe liver injury.¹⁵ Patients who choose oral drug therapies are required to undergo frequent blood testing and must refrain from alcohol consumption during the entire course of treatment.

Topical therapies have become increasingly popular because they pose none of the adverse effects associated with systemic treatment. Topical therapies include Ciclopirox, Amorolofine, Imidazoles, Tolnaftate,

Bifenaflin, Tioconazole, and topical Terbinaflin. With the introduction of trans-ungual delivery, chemical penetration enhancers, bioadhesive polymers, surface modifiers and ultrasound,¹⁶ their efficacy seems to be improving. Topical treatments do not perform well when there is multiple nail involvement, or involvement of more than the distal two-thirds of the nail plate or lunula. Additionally, since these topical therapies do not penetrate the nail plate, efficacy is low and recurrence is high.¹⁷

Device-related therapies such as chemical or surgical debridement as well as laser therapies have become increasingly popular in the treatment of onychomycosis. Laser treatments not only provide aesthetic benefits to the majority of subjects,¹⁸ but they are also effective in clearing the infection by causing photoinactivation of the fungi, inhibiting fungal cell growth.^{19, 20, 21} This study evaluates the efficacy of the PinPointe FootLaser as a valuable treatment option for the management of onychomycosis.

METHODS

Twelve subjects that presented with onychomycosis (seven female and five males with ages ranging from 28-68 years with an average of 50 years) received mechanical debridement followed by treatment with the short-pulsed Nd:YAG (1064nm) PinPointe FootLaser, which has proprietary micropulsing technology not present in long pulse Nd:YAG systems. Nine subjects received one treatment and three subjects received 2-3 treatments. Data following treatment was collected, reviewed and analyzed using planimetry measurements and ImageJ software.

All 12 subjects received extensive and thorough pretreatment mechanical debridement to remove the distal onycholytic nail plate and thin the nail plate to 1mm or less. The nail and surrounding area were cleaned of debris with chlorhexidine spray. Subjects then received treatment with the PinPointe laser. Each 1.5mm spot consisted of 10 micropulses over 0.5 seconds, delivering 22J/cm² over 100 microseconds. Laser spots were administered in a grid pattern with 1.0-1.5mm spacing. Two passes were made using this technique, one transverse, and the other longitudinally, and included 2-3mm surrounding the nail. Of the subjects that received multiple treatments, two subjects received three treatments and one subject received two treatments administered at follow-up office visits.

Posttreatment, subjects are instructed to wash and dry between toes and treat any skin infection such as athlete's foot until resolution. Use of a daily cream comprised of terbinaflin 1%, was recommended for use all over the foot until completion. Afterwards, subjects may use 20g clotrimazole 1% cream. For

long-term care, subjects are instructed to continue use of an antifungal cream daily or at least weekly. Follow-up visits were scheduled at an average of seven months following treatment, and photos were taken at baseline and at the follow-up visits in order to compare lesion reduction and the increase in clear nail area.

PLANIMETRY

Planimetry analysis was used to assess lesion reduction and clear nail growth between pretreatment and post follow-up photos. To achieve consistent magnification, Adobe Photoshop was used by a technician to trace the area of clear nail and the area of infected nail. None of the photos were enhanced or filtered to obtain clear margins between infected and clear nail. To maintain consistency with measurements and evaluation, the following definitions were used:

- **Clear nail:** uniform in color (pink, reddish, flesh, or pale) with smooth surface and normal thickness.
- **Infected nail:** abnormal in color (milk white, black, brown, yellow, green) with flakey, distorted, roughened, ridges, or a thickened nail plate that may be onycholytic.
- **Lesion area:** total infected area including discoloration, thickening and yellowing of nail
- **Lesion area at follow-up:** total infected area at follow-up
- **Clear nail growth:** new clear nail that has grown (%) in comparison to the baseline clear nail area
- **Absolute clear nail:** the baseline lesion area (%) minus the follow-up lesion area (%)
- **Lesion reduction:** the absolute lesion decrease % divided by the baseline lesion area (%)

ImageJ Software

The areas of infected and clear nail were calculated to compare baseline lesion area to the follow-up lesion using ImageJ software. ImageJ is a National Institutes of Health (NIH)-based program designed for image analysis and processing. The program converts images into their individual pixels so that different areas within the image can be analyzed.²² This new analysis tool has been used in several medical disciplines – to accurately count the number of organisms grown in culture,²³ calculate microscopic changes in the kidney that occur with aging,²⁴ and measure differences in muscle composition.²⁵ ImageJ was utilized during the analysis to measure changes in clear nail growth between the baseline and follow-up images from subjects treated with the PinPointe FootLaser.

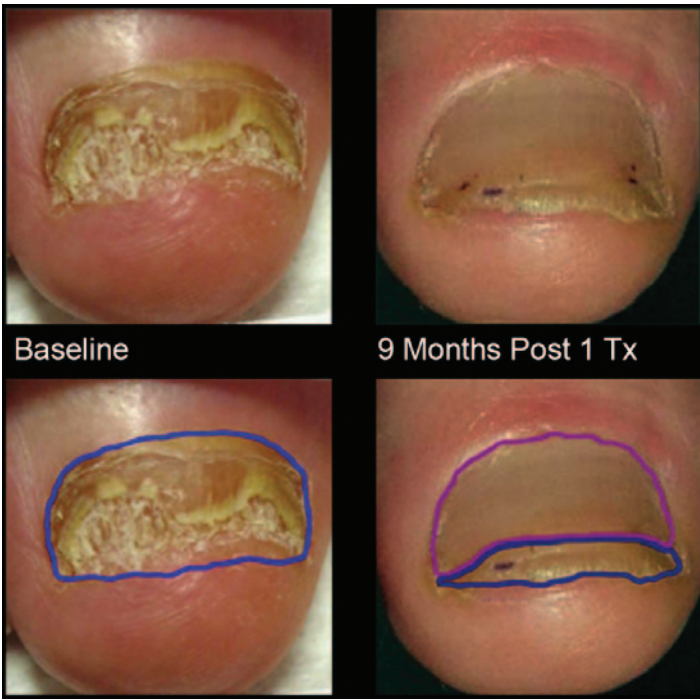


Figure 1: Planimetry outlining of the infected nail (blue) and clear nail (pink). Using ImageJ comparing the relative sizes of infected vs. clear nail, this patient showed a 71% improvement nine months after one treatment using the PinPointe FootLaser.

Table 1
Increase in Clear Nail Area

	Mean Baseline Clear Nail Area	SD	Mean Follow-up Clear Nail Area	SD
1 Treatment	27%	30%	77%	26%
1+ Treatment	1%	2%	71%	18%

Table 2
Lesion Area Reduction

	Mean Baseline Lesion Area	SD	Mean Follow-up Lesion Area	SD	Lesion Reduction (% Baseline)
1 Treatment	73%		23%	26%	68%
1+ Treatment	99%	2%	29%	18%	71%

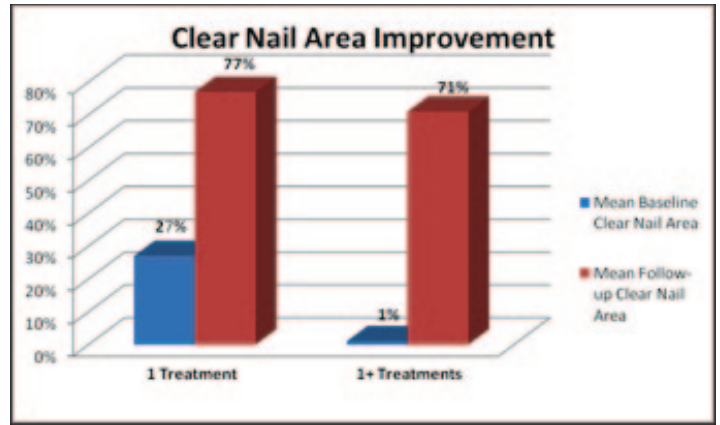


Figure 2: Clear Nail Area Improvement – clear nail improvement between those subjects who received 1 treatment vs. those who received 1+ treatments.

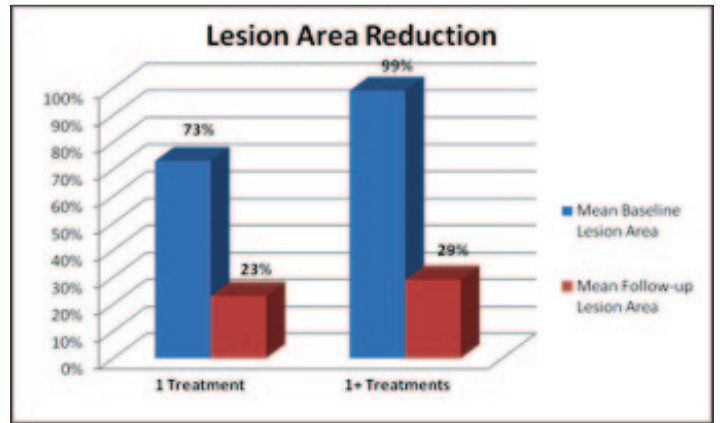


Figure 3: Lesion Area Reduction - lesion area reduction between those subjects who received 1 treatment vs. those who received 1+ treatments.

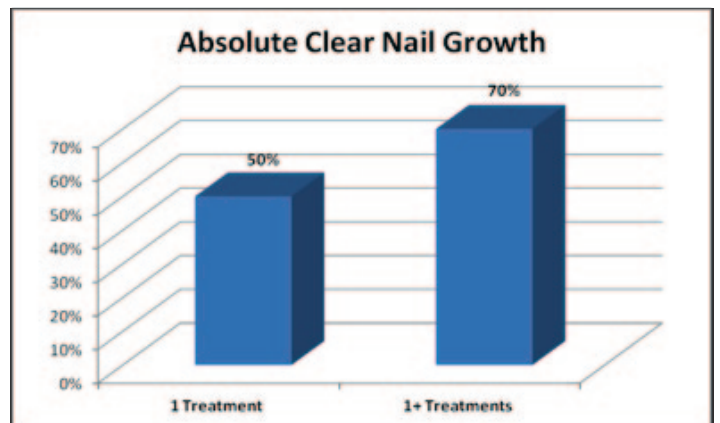

Figure 4: Absolute Clear Nail Growth - absolute clear nail growth between those subjects who received 1 treatment vs. those who received 1+ treatments.