

# Evaluation of a short pulse Nd:YAG Laser Procedure for Infected Nails—A Retrospective International Multicenter Study of 262 Patients

**Chris Horine, DPM**, Neat Feet Podiatry Laser Center, San Jose, CA

**Hamish Dow, DPodM HCPC**, The Dow Clinic & Newcastle Nail Laser Centre, Newcastle upon Tyne, UK

**John Cozzarelli, DPM**, Podiatry Associates of Belleville, Belleville, NJ

## ABSTRACT

**Study Purpose:** To review the clearance of 262 patients (453 great toes) presenting with onychomycosis from three private practices that used the PinPointe™ FootLaser™ and a typical clinical protocol to determine outcomes in the percent of responders as well as percent of clear nail growth and lesion reduction in a subset of the patients. These patients were part of the multi-center study submission to obtain FDA clearance to market for the PinPointe FootLaser.

**Study Design:** In this retrospective study, patients received one PinPointe short-pulsed Nd:YAG FootLaser procedure. Before and after photographs of the great toe were taken at base line and post procedure follow up. Photographs were compared to determine response rate. In addition, planimetry using ImageJ software was used to determine clear nail growth as well as lesion reduction.

**Study Results:** The percent of patients presenting at long-term follow-up intervals with reduced lesion area were 67.7% at 3 months, 70.5% at 6 months, 76.8% at 9 months and 81.5% at one year. Planimetry showed that in the subset of toes where measurements were conducted there was a 100% response rate. A mean of 78% of absolute clear nail area was achieved with a 181% of clear nail growth.

**Conclusions:** Results indicate that the PinPointe FootLaser procedure can improve the percentage of clear nail and reduce the overall lesion size in clinically diagnosed onychomycosis.

## INTRODUCTION

Onychomycosis is a pathogenic infection of the nail that affects an estimated 10-30 million people in the United States alone.<sup>1</sup> In the geriatric population, the prevalence is reportedly as high as 40%.<sup>2,3</sup> This infectious disease can be severe enough to drive millions of patients per year to seek medical treatment. In the setting of underlying conditions, onychomycosis may lead to more severe sequelae, such as opportunistic infections in the case of HIV<sup>4</sup> and amputation in diabetes.<sup>5,6</sup> Further, an infected nail serves as a reservoir of disease that can lead to recurrent *Tinea pedis*.<sup>3</sup> A chronic disease with a high chance of recurrence, onychomycosis is a condition without a cure and in need of methods offering better disease control.

Currently there are two FDA-approved oral antifungal drugs used to treat onychomycosis: 1) oral terbinafine (Lamisil®) and 2) itraconazole (Sporanox®). Oral terbinafine has an efficacy of 35-78%, and itraconazole has consistently lower efficacy.<sup>7,8,9,10</sup> As with any pharmaceutical therapy, these treatments confer potentially serious side effects and drug interactions.<sup>11</sup> In our experience, less than 10% of patients presenting with onychomycosis are eligible for treatment with terbinafine.

In addition to oral antifungal drugs, topical therapies are also indicated for the treatment of onychomycosis. Nail lacquers containing ciclopirox, amorolfine,

tioconazole or a combination of these agents comprise the majority of topical creams available to treat onychomycosis. Topical therapies involve weekly or daily application to the infected nail for a period of nine to twelve months. Despite diligence and consistency in application of the drug, topical therapies such as ciclopirox are effective in about 10% of patients.<sup>13</sup>

Our experience suggests that potentially 90% of patients suffering from onychomycosis may benefit from laser procedures. This paper describes the results of retrospective analysis of before and after photographs of great toes which received the FootLaser procedure. The laser procedure was consistent across practices. A subset of patients has been analyzed to show clearance in nail growth.

## **MATERIALS AND METHODS**

Patients all provided informed consent to use their data anonymously for scientific publication. Patients had a clinical diagnosis of infected nail usually without laboratory verification. A total of 262 patient records with 453 infected great toes were collected, reviewed and analyzed post-procedure and follow up.

## **CLINICAL PROTOCOL**

Patients all received routine medical management of their conditions. The clinical protocol included pre-procedure debridement, which incorporated removal of distal onycholytic nail plate and thinning of hypertrophic nail plate to a thickness of 1 mm or less using a high-speed burr. Toes were not anesthetized for the procedure. The laser used was the PinPointe short-pulsed Nd:YAG FootLaser (NuvoLase Inc., Chico CA 95973). A single spot consisted of a pulse train of ten 255 mJ, 90  $\mu$ s duration pulses at 1064 nm, delivered into a 1.5 mm spot with ergonomic timing and audible alert to allow precise movement by the practitioner. Laser spots were delivered in a grid pattern with 1.0-1.5 mm spacing. The total light dose averaged 115 J/cm<sup>2</sup> per pass over the entire nail plate plus a 2-5 mm margin. One or two laser passes were used with the FootLaser on one or both great toes. Other toes usually received the FootLaser procedure but are not included in this analysis. A topical antifungal was applied after the procedure and the patient was instructed in its daily use.

Additional foot hygiene instructions were given and patients were followed at approximately three-month intervals. Patient's used the SteriShoe<sup>®</sup> product to sanitize their shoes. Great toe photos were obtained of toes before the procedure and at follow ups, to a maximum of 10 months post-procedure. The photographs were compared to assess response rate. In a subset of five toes planimetry was used to calculate clear nail growth and lesion reduction.

## **PLANIMETRY OF PHOTOGRAPHS**

Patients were included in the analysis if they had a usable baseline photo and at least one useable follow-up photo. The photo had to be of sufficient quality to clearly visualize the extent of the entire nail plate. Planimetry was performed to measure lesion reduction and clear nail growth on a subset of patients.

The total nail plate area is defined by the anatomical boundaries of the hyponychium distally, the lateral folds medially and laterally and the eponychium (cuticle) proximally. The hyponychium is a stationary anatomical landmark and is identified as the distal boundary independent of the variable distal location of the nail plate. In most cases the area bounded by the hyponychium distally and the infected /clear nail boundary proximally is the "lesion." The area from the boundary to the eponychium is "clear nail." The boundary between lesion and clear nail was often evident but sometimes ambiguous.

Since this was a retrospective study, the images of the great toe that were submitted for analysis lacked a distance scale and Adobe Photoshop was used to achieve a consistent magnification. Photos were neither enhanced nor filtered hence the margin between clear and infected nail was unaffected. Using Adobe<sup>®</sup> Photoshop<sup>®</sup>, a technician traced the area of clear nail and the area of infected nail. To achieve consistency with measurements and evaluation the following defining criteria was used: Clear nail was defined with objective criteria as a uniform pink coloring, reddish, flesh or pale; smooth surface and normal thickness. Areas that are slightly discolored but smooth and normal thickness are generally considered clear. Infected nail was defined with objective criteria as a milky white, black, brown, yellow or occasionally green color.

Areas with distal or proximal spikes are considered infected. The nail plate may be smooth but more often flakey, distorted, roughened, ridged and/or thickened. The nail plate may be separated from the nail bed (onycholytic) (Figures 1,2 )The photos which outlined the clear and infected nail area were opened in ImageJ software and measurements were taken. The area was calculated in pixels which was then used to represent the area of the lesion at the baseline and the follow up time point.

The baseline lesion area was defined as the total infected area including discoloration, thickening and yellowing of the nail at baseline. The follow up lesion area is defined as the total infected area including discoloration, thickening and yellowing of the nail at the follow up time point. The lesion reduction (% of baseline) was then calculated by dividing the absolute lesion decrease (%) by the baseline lesion area (%).

Student's T-test was performed and p-values lower than 0.5 were considered significant. Standard deviation was calculated to determine the variation that existed from average.

## RESULTS

Patient photos meeting study criteria yielded results from 262 patients. Of these, 51% were male and 49% were female. The mean age of the patients was 53.8 years (range= Ages10-87, SD=14.6). The ethnicity was 90% Caucasian, with an additional 4% Asian, 3% Hispanic, 2% African-American and 1% other. The useable photo sample included 453 great toes that had received the laser procedure.

The percent of patients presenting at long-term follow-up intervals with reduced lesion area were 67.7% at 3 months, 70.5% at 6 months, 76.8% at 9 months and 81.5% at one year.

### Increase in Clear Nail Area and Lesion Reduction in Subset of Toes

A subset of 5 toes that were measured by planimetry showed that 100% of patients responded and had an increase in clear nail growth at follow up. The mean baseline clear nail area was 28% ( $\pm 32\%$ ) of the nail. After an average of 7 months post procedure the clear nail area was increased to 78% ( $\pm 6\%$ ) of the nail. Using these two measurements, the clear nail growth (% baseline) was calculated to be 181%. (Table 1, Figure 3).

## DISCUSSION

This study evaluated the PinPointe Short-Pulsed Nd:YAG as a laser procedure option for the temporary improvement in clear nail in patients with onychomycosis. The PinPointe laser utilizes the 1064 nm wavelength which has the ability to pass through the nail plate into the nail bed of the toe. As a result, the fungal material in the nail bed is heated to very high temperatures which inhibits growth, causes damage, and targets dermatophyte cells. As the temperature beneath the nail plate increases, chemical reactions that promote fungal cell growth occur less efficiently and growth slows. Eventually as the temperature reaches a certain point, growth completely stops and cell components such as enzymes and cell membranes are damaged by the heat. Hashimoto and Blumenthal studied the effect of heat on dermatophyte arthrospores and found that arthrospores of *T. Rubum*, the primary dermatophyte that causes onychomycosis, were sensitive to heat. This indicated that heat may destroy most of the dermatophytes and the spores they produce. Vural et al further studied the inhibitory effect of heat on dermatophyte cells. They found that the laser procedure with the 1064 nm wavelength resulted in a much slower growth rate, indicating that the laser energy was inhibiting the growth of the dermatophytes. They suggested that the 1064 nm might be useful in targeting not only the dermatophyte cells but the blood supply associated with their viability because this wavelength is readily absorbed by Hemoglobin.

Studies evaluating the efficacy of oral and topical antifungal treatments measured improvement and reported data based on complete cure of onychomycosis. The success of topical treatments was low (7% for Sporanox) due to the inability of the medication to reach the nail bed, long treatment time (9-12 months) and dependency on patient compliance.<sup>14,16</sup> Efficacy of oral terbinafine was variable (35%-78%) which can be attributed to antibiotic resistance and dependency on patient compliance.<sup>8,9,10</sup>

In this study, efficacy of the 1064 nm laser was measured based on clear nail growth and reduced lesion area. Both measurements showed a significant improvement with 78% clear nail growth and a decrease in the lesion from 72% at baseline to 22% after an average of 7 months. The laser procedure

also improved the quality of the nail (Figure 2) further increasing patient satisfaction. When comparing this study to the use of oral and topical antifungals, the use of the 1064 Nd:YAG laser has provided an alternative option which has demonstrated significant efficacy for the temporary improvement in clear nail in patients with onychomycosis.

In addition to a very prominent laser procedure effect, it is possible that long term efficacy of at least 1 year is influenced by the improved medical management, changing to appropriate footwear, prescribed regular use of topical antifungal treatments, ways to avoid toe trauma and reinfection is a partial list of advice given to patients in this study. One expects that these will all improve the clinical outcome, although used alone, historically, these remedies have been disappointing. Still, the possible effects of aftercare should be considered in interpreting these retrospective data. The most conservative conclusion of this study could be that a procedure with the laser, embedded in a program of proper management, results in overall improvement in the percentage of clear nail.

The sample in this study represents a cross section of the actual patient population. These were patients with a clinical diagnosis of toenail infection who had elected the FootLaser procedure with the cosmetic goal of improvement in nail appearance and increase in clear nail without toxic systemic side effects. The laser procedure was not restricted to only patients with laboratory confirmed dermatophyte infections. Podiatrists are experienced in diagnosis of psoriatic nails, onycholysis, onychogryphosis, onychomycosis and trauma. It is understood that the infected nail is typically a mixed species infection including dermatophytes, molds, yeasts and bacteria.

## CONCLUSION

The use of the PinPointe FootLaser has proven to be an effective procedure option for the temporary improvement of clear nail in patients with onychomycosis. Patients in this study experienced 181% new nail growth reducing the average lesion from 72% at base line to 22% at follow up.

## ACKNOWLEDGMENTS

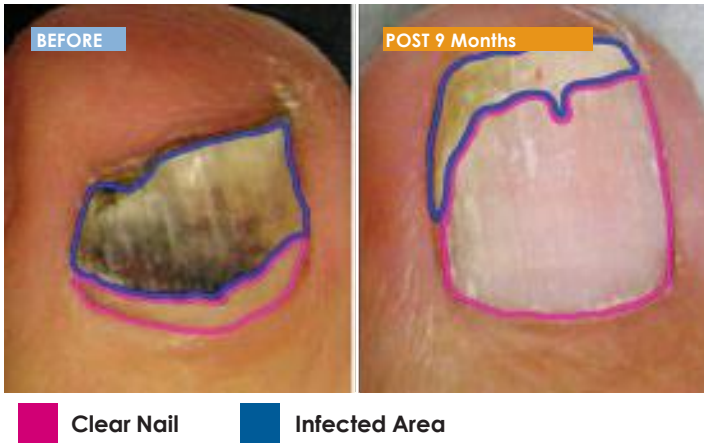
The co-authors have no financial interest in the PinPointe FootLaser.

## REFERENCES

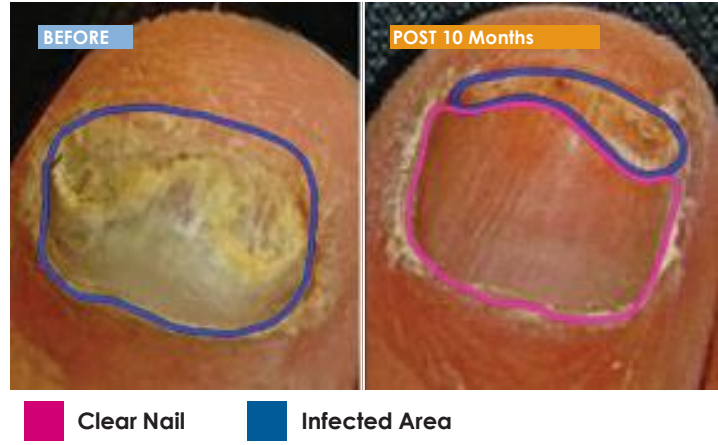
- 1 B.E. Elewski, "Onychomycosis: pathogenesis, diagnosis, and management," *Clinical Microbiology Reviews*, vol. 11, Jul. 1998, pp. 415-429.
- 2 G. Botek, "Fungal nail infection: assessing the new treatment options," *Cleveland Clinic Journal of Medicine*, vol. 70, Feb. 2003, pp. 110-114.
- 3 A.K. Gupta, P. Taborda, V. Taborda, J. Gilmour, A. Rachlis, I. Salit, M.A. Gupta, P. MacDonald, E.A. Cooper, and R.C. Summerbell, "Epidemiology and prevalence of onychomycosis in HIV-positive individuals," *International Journal of Dermatology*, vol. 39, 2000, pp. 746-753.
- 4 J.A. Winston and J.L. Miller, "Treatment of onychomycosis in diabetic patients," *Clinical Diabetes*, vol. 24, Oct. 2006, pp. 160-166.
- 5 A.K. Gupta and S. Humke, "The prevalence and management of onychomycosis in diabetic patients," *European Journal of Dermatology*, vol. 10, 2000, pp. 379-384.
- 6 FDA. Penlac product insert. Available at: [http://www.accessdata.fda.gov/drugsatfda\\_docs/label/2004/21022s004lbl.pdf](http://www.accessdata.fda.gov/drugsatfda_docs/label/2004/21022s004lbl.pdf). Accessed on 2/29/12.
- 7 M.B. Jennings, R. Pollak, L.B. Harkless, F. Kianifard, and A. Tavakkol, "Treatment of toenail onychomycosis with oral Terbinafine plus aggressive debridement: IRON-CLAD, a large, randomized, open-label, multicenter trial," *Journal of the American Podiatric Medical Association*, vol. 96, Nov. 2006, pp. 465-473.
- 8 A.K. Gupta, J. Ryder, and A. Johnson, "Cumulative meta-analysis of systemic antifungal agents for the treatment of onychomycosis," *British Journal of Dermatology*, vol. 150, 2004, pp. 537-544.
- 9 Sigurgeirsson B, Billstein S, Rantanen T, Ruzicka T, di Fonzo E, Vermeer BJ, Goodfield MJ, Evans EG. LI.ON. Study: efficacy and tolerability of continuous terbinafine (Lamisil) compared to intermittent itraconazole in the treatment of toenail onychomycosis. Lamisil vs. Itraconazole in Onychomycosis. *Br J Dermatol*. 1999 Nov;141 Suppl 56:5-14.
- 10 K. Agarwal, D.M. Manas, and M. Hudson, "Terbinafine and fulminant hepatic failure," *N. Eng. J. of Med.*, vol. 340, 1999, pp. 1292-1293.
- 11 Harris DM, J Strisower, B McDowell (2009). Pulsed laser treatment for toenail fungus. SPIE Proceedings 7161A-121.
- 12 Welsh O, L Vera-Cabrera, E Welsh. "Onychomycosis." *Clinics in Dermatology*. 2010; 28: 151-159.
- 13 H. Heikila and S. Stubb, "Long-term result in patients with onychomycosis treated with terbinafine or itraconazole," *British Journal of Dermatology*, vol. 146, 2002, pp. 250-253.
- 14 Hochman L. Laser Treatment of onychomycosis using a novel 0.65-millisecond pulsed Nd:YAG 1064-nm laser. *Journal of Cosmetic and Laser Therapy*. 2011; 13: 2-5
- 15 Burge H. How does heat affect fungi? *The Environmental Reporter*. 2006;4(3):March
- 16 Hashimoto T, Blumenthal HJ. Survival and Resistance of Trichophyton mentagrophytes arthrospores. *Appl Environ Microbiol*. 1978;35(2):274-7
- 17 Uro M, L Uro, M Abrahams, M Abrahams, R Grzywacz. Safety and efficacy of FootLaser treatment of onychomycosis in private practice. *Lasers Surg Med* 2011; 43(S23):954 (abstr).



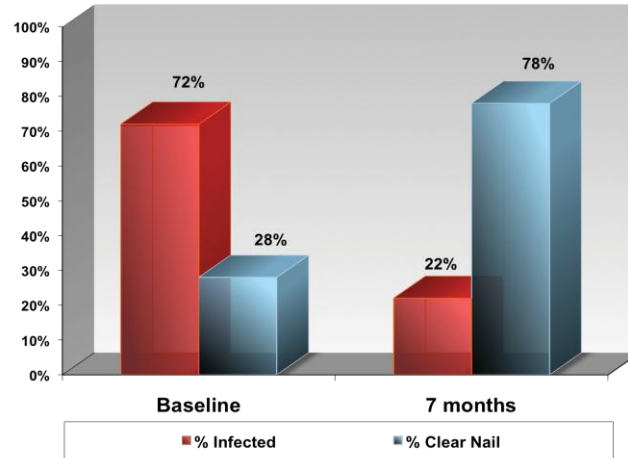
**Figure 1. Subject ES Planimetry Analysis**



**Figure 2. Subject LA Planimetry Analysis**



**Figure 3. Average percent of nail that was infected or clear at baseline and follow up**



**Table 1.** Improvement is quantified by increase in clear nail growth

### Clear Nail Growth Determined by Area Calculated in Image J

Follow-Up period Average	# of toes	Mean Baseline Clear Nail Area	Std. Dev.	Mean Follow-up Clear Nail Area	Std. Dev.	Clear Nail Growth (% Baseline)	% of Patients with Increase in Clear Nail
7 months	5	28%	32%	78%	6%	181%*	100%

\*p-value=.016, p-value lower than .05 is considered significant

The mean lesion area at baseline was determined to be 72% ( $\pm 22\%$ ) of the nail and was reduced to 22% ( $\pm 6\%$ ) of the nail at follow up. Based on the mean baseline lesion area and the mean follow up lesion area, lesion reduction was calculated to be 69%. (Table 2, Figure 3).

**Table 2.** Improvement is quantified as the lesion area reduction (% baseline)

### Lesion Reduction Determined by Area Calculated in Image J

Follow-Up period Average	# of toes	Mean Baseline Lesion Area	Std. Dev.	Mean Follow-up Lesion Area	Std. Dev.	Lesion Reduction (% Baseline)	% of Patients with Reduced Lesion Area
7 months	5	72%	22%	22%	6%	69%*	100%

\*p-value=.016, p-value lower than .05 is considered significant



[www.nuvolase.com](http://www.nuvolase.com)

NuvoLase, Inc.  
11 Ilahee Lane  
Chico, CA 95973  
530-809-1970

© PinPointe and Footlaser are trademarks of NuvoLase Inc.  
LIT0170 Rev. B

